

## Acute Posterior Multifocal Placoid Pigment Epitheliopathy (APMPPE)

Khayyam Durani, M.D.

### Case Report

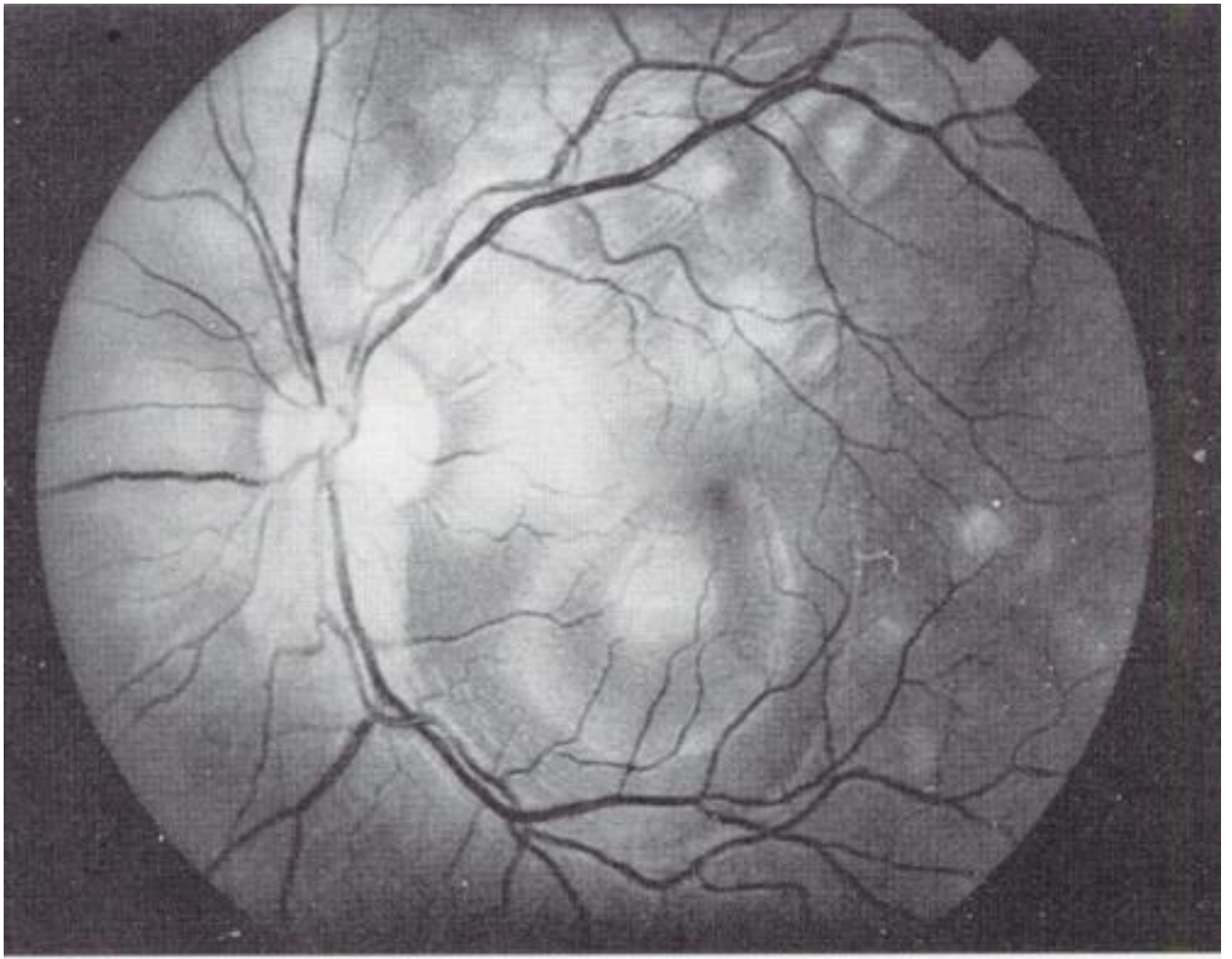
A 29 year-old female presented with a sudden bilateral onset of decreased vision occurring one day prior to presentation. Examination revealed mild rhinorrhea and pharyngeal hyperemia, visual acuities of 20/400 and counting fingers at 4 feet in the right and left eyes respectively. External and slit lamp examinations were unremarkable, and intraocular pressures were within normal limits. Fundus examination revealed numerous discrete yellow lesions involving the macula as well as the peripheral retina (Figs. 1,2). A fluorescein angiogram was obtained, and showed bilateral multifocal hypofluorescent lesions with hyperfluorescence during the late venous stages of the study, evident in both eyes several minutes following injection (Figs. 3, 4).

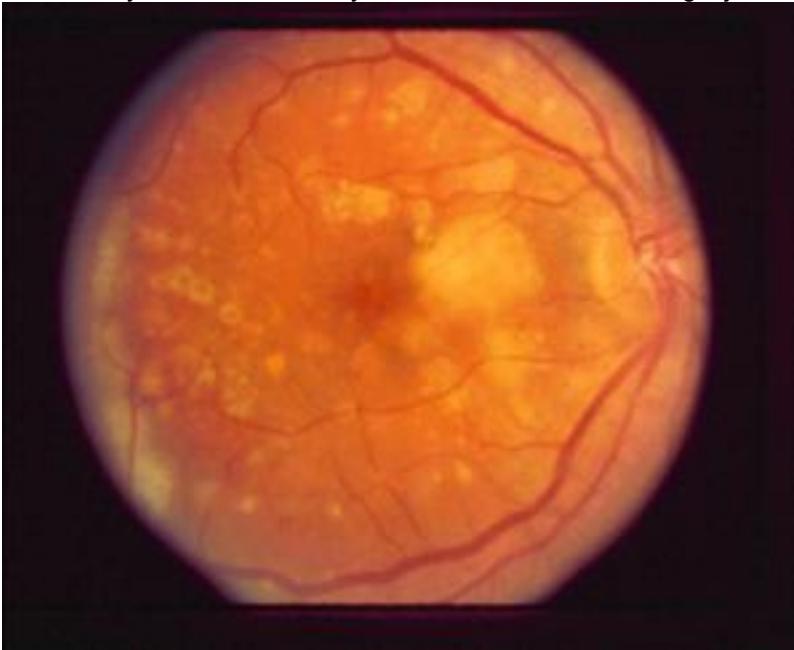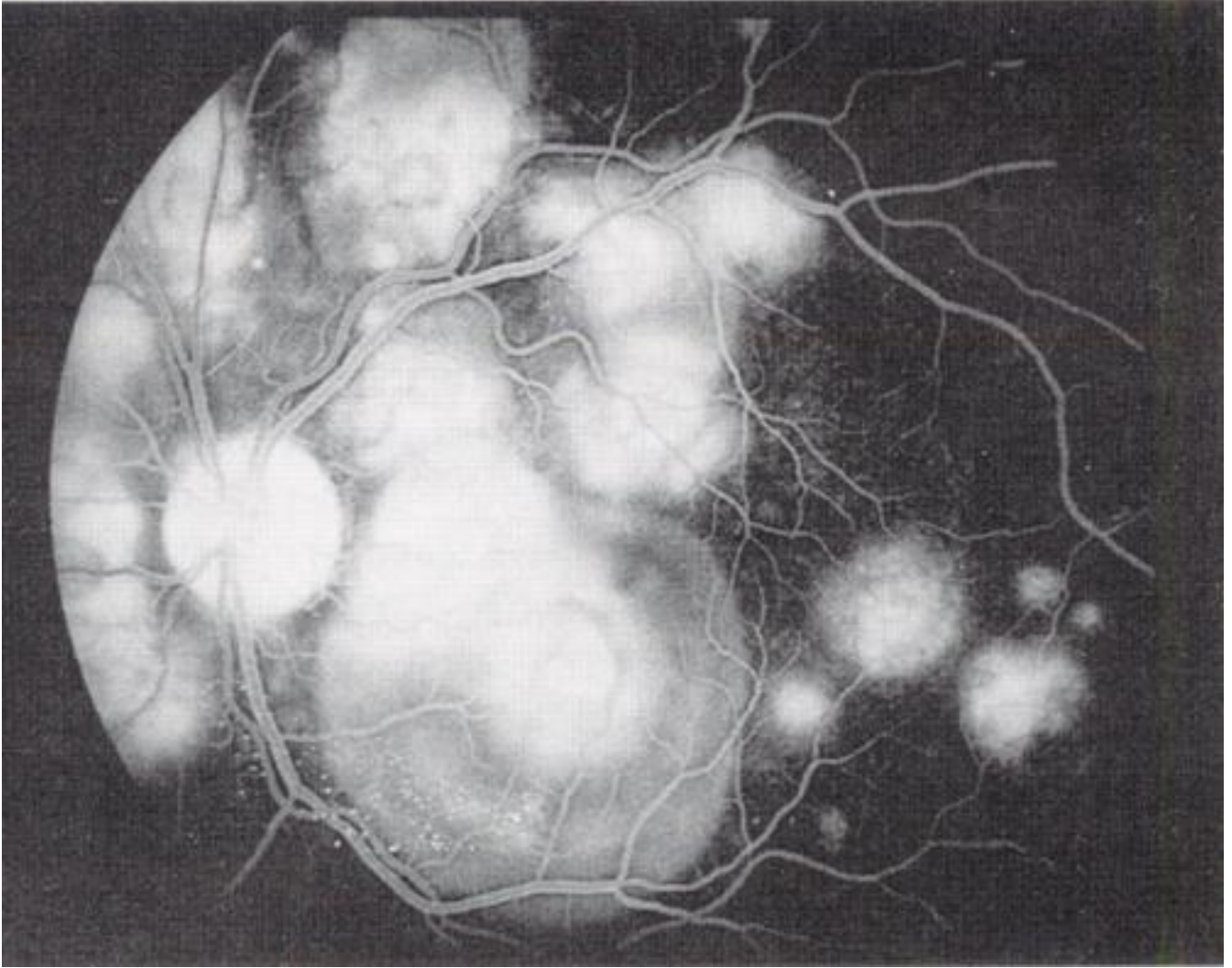


Figure 1 Fundus photograph, right eye.

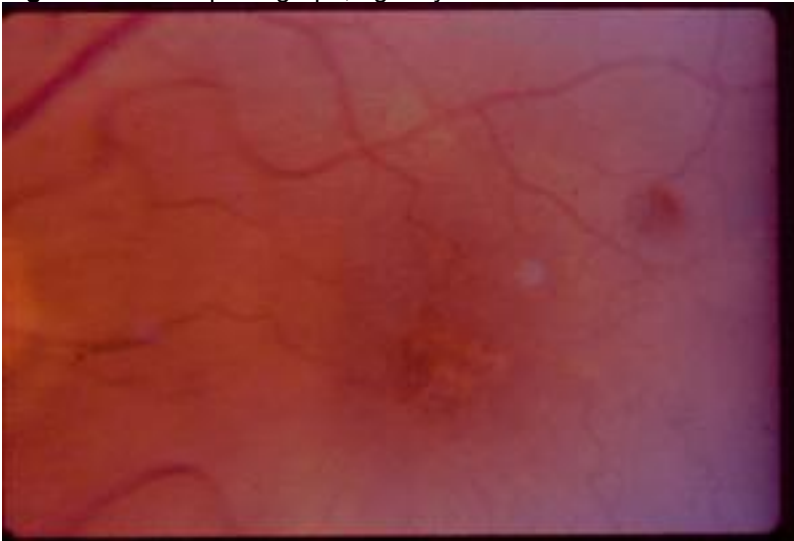

Figure 2 Fundus photograph, left eye. A close-up view of the macula.





**Figures 3 and 4** Fluorescein angiograms, left eye. Early blockage of fluorescence in the region of the lesions observed, followed by late staining in the same areas.

A diagnosis of acute posterior multifocal pigment epitheliopathy was made and the patient was treated with oral prednisone, 1 mg/kg per day for 1 week, followed by a gradual taper and discontinuation of the drug over the following four weeks. Vision improved to 20/20 in the right eye and 20/30 in the left at six weeks of follow up, and the patient has had no recurrence of symptoms during the subsequent follow up period.

### **Acute Posterior Multifocal Placoid Pigment Epitheliopathy (APMPPE)**

#### **Definition**

Originally described by Gass in 1968, acute posterior multifocal pigment epitheliopathy (APMPPE), is a disorder characterized by the sudden appearance of multiple, yellow-white, flat inflammatory lesions at the level of the retinal pigment epithelium and choriocapillaris.<sup>1</sup> Although surrounded by considerable controversy, the pathogenesis and etiology of this disease remain unclear.

#### **Epidemiology**

APMPPE is a rare entity, diagnosed in only five patients over one 10-year period at the Immunology and Uveitis Service of the Massachusetts Eye & Ear Infirmary.<sup>2</sup> Owing to the rarity

of the disease, accurate estimates of the incidence and prevalence of the disease are unavailable. It does appear, however, that cases of APMPEE may occur in clusters.<sup>3</sup> The disorder occurs most commonly between the ages of 20 and 30 years, with a range of 8 to 66 years. The disorder is thought to occur more commonly in Caucasians, and both sexes appear to be affected equally.<sup>4</sup>

### **Clinical Characteristics**

A flu-like prodrome consisting of fever, malaise and headache precedes most cases of APMPEE. This is followed by a sudden, usually bilateral, painless loss of vision. In patients with a monocular onset of symptoms, involvement of the fellow eye may occur within the following days to weeks. Central or paracentral scotomas may occur in patients with retinal lesions involving the foveal or parafoveal areas. Fundus examination reveals the characteristic multiple round, circumscribed, flat, yellow-white subretinal lesions involving the retinal pigment epithelium.<sup>5</sup> As these lesions resolve over several weeks, vision improves in most cases to slightly less than initial acuity, and in some patients acuity may return to pre-onset levels.<sup>6</sup> With time, fundus lesions are replaced by areas of depigmentation and pigment epithelial clumping. Some patients, however, may develop new lesions during this period of resolution, with areas of inflammation occurring both in previously unaffected retina as well as adjacent to healing areas of epitheliopathy. Additional ocular findings may include episcleritis, anterior uveitis, vitritis, retinal vasculitis, and papillitis.<sup>7-9</sup> Associations with adenovirus type 5 infection, cerebral vasculitis, and erythema nodosum along with a host of immune-mediated disorders have been reported.<sup>9-12</sup> For this reason, it is suggested that all patients with APMPEE undergo a systemic and neurologic evaluation.

Fluorescein angiography reveals characteristic changes during the evolution of the disease. During the acute, active stage of the disease, early films disclose areas of hypofluorescence in inflamed areas secondary to RPE cell edema, leukocyte infiltration, and capillary nonperfusion. However, hyperfluorescence occurs in late films, as leakage occurs from the choriocapillaris through damaged RPE cells, and persists for up to 30 minutes.<sup>5</sup> During the inactive stage, as APMPEE lesions resolve, areas of hyperfluorescence occur at these sites secondary to RPE atrophy and depigmentation. Indocyanine green angiography reveals areas of choroidal hypofluorescence during the acute stage of the disease, resulting from capillary non-perfusion, and these persist during the later stages of the disease, albeit becoming smaller and less pronounced as the lesions heal.

### **Pathogenesis**

There are two schools of thought regarding the site of primary involvement in APMPEE. Gass and colleagues suggest inflammation begins at the level of the retinal pigment epithelium.<sup>13</sup> Others, however, propose that the disorder primarily involves the choriocapillaris, and acute inflammation at this level occurs secondary to a hypersensitivity reaction to an external antigen and leading to occlusion of choroidal arterioles, ischemia, and secondary RPE changes.<sup>14</sup>

Evidence that APMPEE may occur as a result of hypersensitivity to microbial antigens is borne by the fact that an antecedent flu-like illness is reported in the majority of cases, and the disorder has occurred following hepatitis B vaccination, mumps, swine flu vaccination, and bacterial infection.<sup>8</sup> There is an increased incidence of positive PPD skin tests in affected individuals. In addition, certain HLA haplotypes have been shown to be associated with the disorder, with 56.7% of patients with APMPEE reported to be HLA-DR2 positive, in one series, while 40% express HLA-B7. These MHC proteins may present viral or bacterial antigens to helper and cytotoxic T cells and activate the immune response leading to capillary and pigment epithelial cell inflammation.<sup>15</sup>

It has been suggested that inflammatory damage in APMPEE is mediated by a type IV hypersensitivity reaction, and many lines of evidence appear to support this notion. As mentioned previously, tuberculin skin tests are found to be positive on many patients with APMPEE. Granulomatous inflammation was also observed in the vessel walls of two patients with APMPEE

and cerebral vasculitis, and one patient with sarcoidosis and co-existing APMPE on renal biopsy.<sup>16</sup> The disorder also occurs in patients with associated disorders with a proven or purported pathogenesis based on delayed-type hypersensitivity, including thyroiditis, erythema nodosum, microvascular nephropathy, as well as retinal vasculitis.<sup>11,12</sup>

### **Differential Diagnosis**

The diagnosis of APMPE is confirmed by the appearance of the pathognomic retinal lesions described above. Similarities, however, exist between this disorder and serpiginous choroiditis. The latter may be differentiated from APMPE by the fact that lesions in serpiginous choroiditis are localized to the posterior pole and produce a more profound choroidal atrophy. Serpiginous choroiditis also resolves more slowly as compared to AMPPE and patients have a poorer visual prognosis, with recurrences of inflammation occurring more frequently.<sup>17</sup> Some patients with Harada's disease may develop multifocal, gray-white patches at the level of the retinal pigment epithelium similar to, although less well defined than those seen in AMPPE. The accumulation of dye in the subretinal space in Harada's disease, however, serves to differentiate the two conditions on fluorescein angiography.

### **Management**

We suggest that all patients with a diagnosis of APMPE have a neurologic and systemic evaluation primarily directed at excluding the possibility of cerebral vasculitis, sarcoidosis, subclinical nephropathy, thyroiditis, and tuberculosis. Although the ocular disease has a self-limiting course, with approximately 80% of untreated patients having a visual acuity of 20/40 or better, a full 20% are left with impaired vision.<sup>18</sup> We suggest, therefore, that all patients with APMPE with macular involvement be treated with systemic steroids. Our experience suggests that prompt use of systemic steroids rapidly resolves inflammation, and may result in a better visual prognosis. Patients with this condition associated with neurologic disease improve with a combination of steroid and cytotoxic therapy with Cyclosporin A. <sup>19</sup>

### **Summary**

Acute posterior multifocal placoid pigment epitheliopathy is a rare, idiopathic disorder characterized by discrete areas of subretinal inflammation. The condition may be associated with a number of systemic conditions, particularly cerebral vasculitis, and thus warrants a detailed systemic workup. Although the disease is self-limited and has been reported to have a relatively good prognosis, we suggest all patients with macular involvement be treated with systemic steroids in an effort to preserve visual acuity to the greatest extent possible.

### **References**

1. Gass JDM: Acute posterior multifocal pigment epitheliopathy. *Arch Ophthalmol* 1968;80:177-185
2. Rodriguez A, Calogne M, Pedroza-Seres M, et al: Referral patterns of uveitis in a tertiary eye care center. *Arch Ophthalmol* 1996;114:593-599
3. Wolf MD, Folk JC, Goeken EN: Acute placoid multifocal epitheliopathy and optic neuritis in a family. *Am J Ophthalmol* 1990;110:89-90
4. Ryan SJ, Maumenee AE: Acute posterior multifocal pigment epitheliopathy. *Am J Ophthalmol* 1972;74:1066-1074
5. Pedroza-Seres M: Acute posterior multifocal placoid pigment epitheliopathy. In: *Diagnosis and Treatment of Uveitis*. Foster CS, Vitale ST Eds. Philadelphia, W.B.Saunders, 2002, pp 772-778
6. Annesley EH, Tomer TL, Shields JA: Multifocal Placoid pigment epitheliopathy. *Am J Ophthalmol* 1973;76:511-518
7. Fitzpatrick PJ, Robertson DM: Acute placoid multifocal pigment epitheliopathy. *Arch Ophthalmol* 1973;89:373-376
8. Holt WS, Regan CDJ, Trempe C: Acute placoid multifocal pigment epitheliopathy. *Am J Ophthalmol* 1976;81:403-412

9. Savino PJ, Weinberg RJ, Yassin JG, Pilkerton AR: Diverse manifestations of acute posterior multifocal placoid pigment epitheliopathy. *Am J Ophthalmol* 1974;77:659-662
10. Azar P, Gohd RS, Waltman D, Gitter KA: Acute posterior multifocal placoid pigment epitheliopathy associated with adenovirus type 5 infection. *Am J Ophthalmol* 1975;80:1003-1005
11. Van Buskirk EM, Lessell S, Friedman E: Pigment epitheliopathy and erythema nodosum. *Arch Ophthalmol* 1971;85:369-372
12. Jacklin HN: Acute posterior multifocal placoid pigment epitheliopathy and thyroiditis. *Arch Ophthalmol* 1977;95:189-194
13. Gass JDM: Inflammatory diseases of the retina and choroid. In: *Stereoscopic atlas of Macular diseases. Diagnosis and Treatment*, 4th ed, St. Louis, C.V. Mosby, 1997, pp 668-675
14. Deutman AF, Lion F: Choriocapillaris non-perfusion in acute posterior multifocal placoid pigment epitheliopathy. *Am J Ophthalmol* 1977;84:45-49
15. Wolf MD, Folk JC, Pankene CA, Goeken EN: HLA B7 and HLA DR2 antigens and acute placoid multifocal pigment epitheliopathy. *Arch Ophthalmol* 1990;108:698-700
16. Park D, Schatz H, McDonald HR et al: Acute multifocal posterior placoid epitheliopathy: A theory of pathogenesis. *Retina* 1995;15:351-352
17. Nussenblatt RB, Whitcup SM, Palestine AG: *Uveitis: Fundamentals and Clinical Practice*, 2nd ed, St. Louis, C.V. Mosby, 1996, pp 364-384
18. Williams DF, Mieler WF: Long-term follow-up of acute placoid multifocal pigment epitheliopathy. *Br J Ophthalmol* 1989;73:985-990
19. Bridges WJ, Saadeh C, Gerald R: Acute placoid multifocal pigment epitheliopathy in a patient with systemic-onset juvenile rheumatoid arthritis: Treatment with Cyclosporin A and prednisone. *Arthritis Rheum* 1995;38:446-447

## **20. Acute posterior multifocal placoid pigment epitheliopathy (APMPPE)**

21. **Khayyam Durani, M.D.**

22. Review Questions
23. Q. 1) Acute posterior multifocal placoid pigment epitheliopathy (APMPPE) most commonly occurs in
24. a) the elderly
25. b) Caucasians
26. c) Men
27. d) the pediatric population
28. Q. 2) The disorder has been associated with
29. a) cerebral vasculitis
30. b) thyroiditis
31. c) erythema nodosum
32. d) a microvascular granulomatous nephritis
33. Q. 3) Fluorescein angiographic findings in APMPPE include the following
34. a) early hypofluorescent lesions
35. b) early hyperfluorescent lesions
36. c) hypofluorescent areas during the late venous phase
37. d) hyperfluorescence during the late venous phase
38. Q. 4) The disorder has been associated with the following HLA haplotypes:
39. a) HLA- B5
40. b) HLA- B27
41. c) HLA- B7
42. d) HLA- DR2
43. Q. 5) The two most important differential diagnoses in APMPPE are
44. a) Presumed ocular histoplasmosis syndrome
45. b) Serpiginous choroiditis
46. c) Adamantiades Behcet Disease
47. d) Vogt- Koyanagi- Harada Syndrome
48. Q. 6) The onset of APMPPE is characterized by a gradual loss of vision. T/F

49. Q. 7) Indocyanine green angiography in affected patients reveals well-circumscribed, hyperfluorescent lesions. T/F
50. Q. 8) The pathogenesis of APMPE may involve infection and presentation of microbial antigens with specific MHC proteins in susceptible individuals. T/F
51. Q. 9) Patients with APMPE with macular involvement should be treated with systemic steroids T/F
52. Q.10) There is evidence to indicate that this disorder may be a Type III hypersensitivity reaction against choriocapillaris basement membrane T/F
53. Answers
54. Q.1) b
55. Q.2) a,b,c,d
56. Q.3) a, d
57. Q.4) c,d
58. Q.5) b,d
59. Q.6) F
60. Q.7) F
61. Q.8) T
62. Q.9) T
63. Q.10) F