

Punctate Inner Choroiditis
David S. Chu, M.D.

Case

Chief Complaint and History of Present Illness

30 year-old Caucasian female presented for a consultation. She has been experiencing recurrent metamorphopsia in both eyes, but affecting one eye at a time for the past two years. Initially, she had transient grayish discoloration of central vision. She was told that she had choroiditis and received a few courses of oral steroids. She also underwent three sessions of laser treatment, one session for the left eye and two for the right.

Past Ocular History

Patient is myopic

Past Medical History

She had Chlamydial infection 12 years ago, which was treated.

She doesn't take any eye drops and review of system is negative.

Examination

Vision - best corrected: 20/50 OD, 20/30 OS

No APD

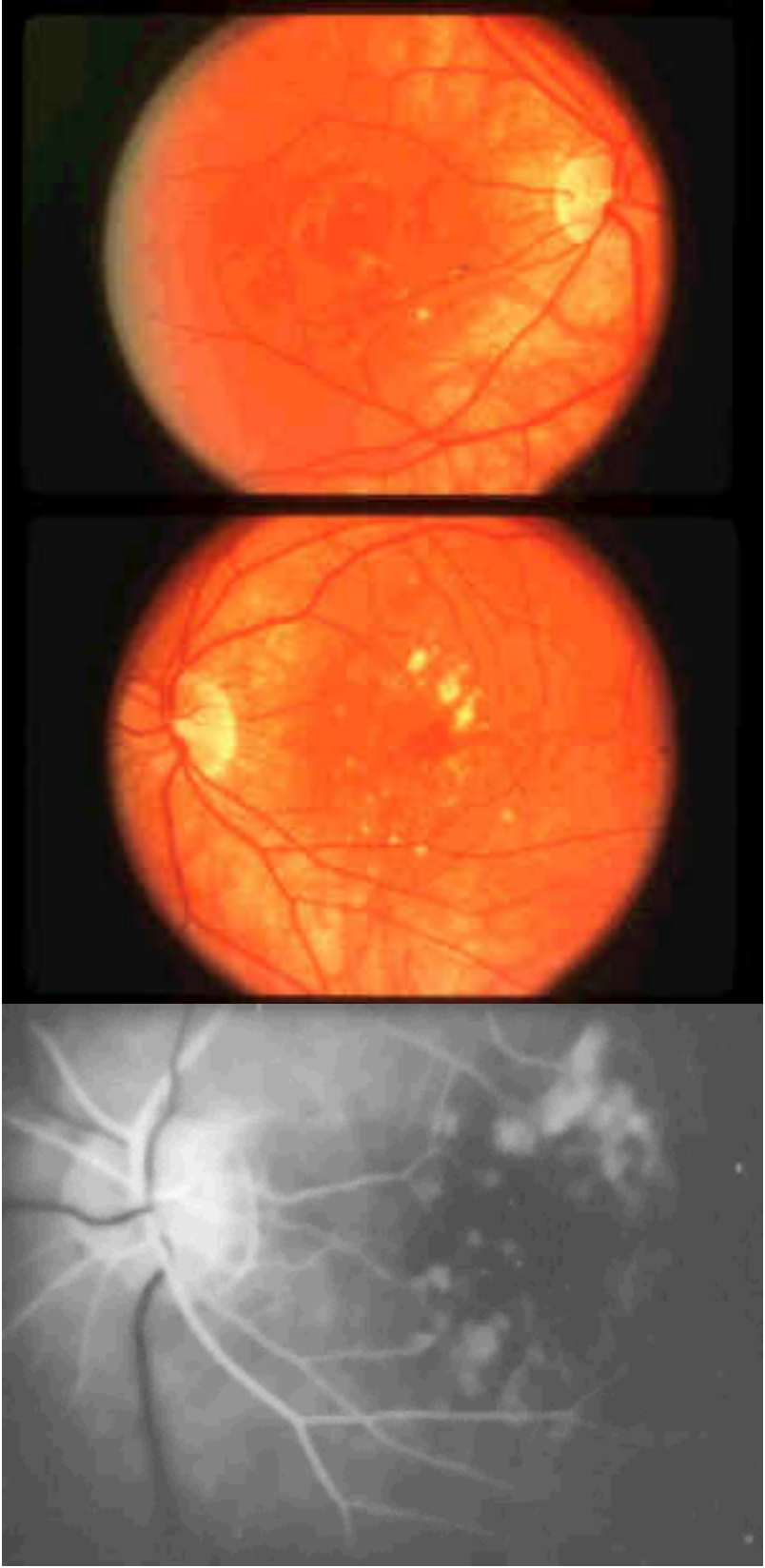
EOM full

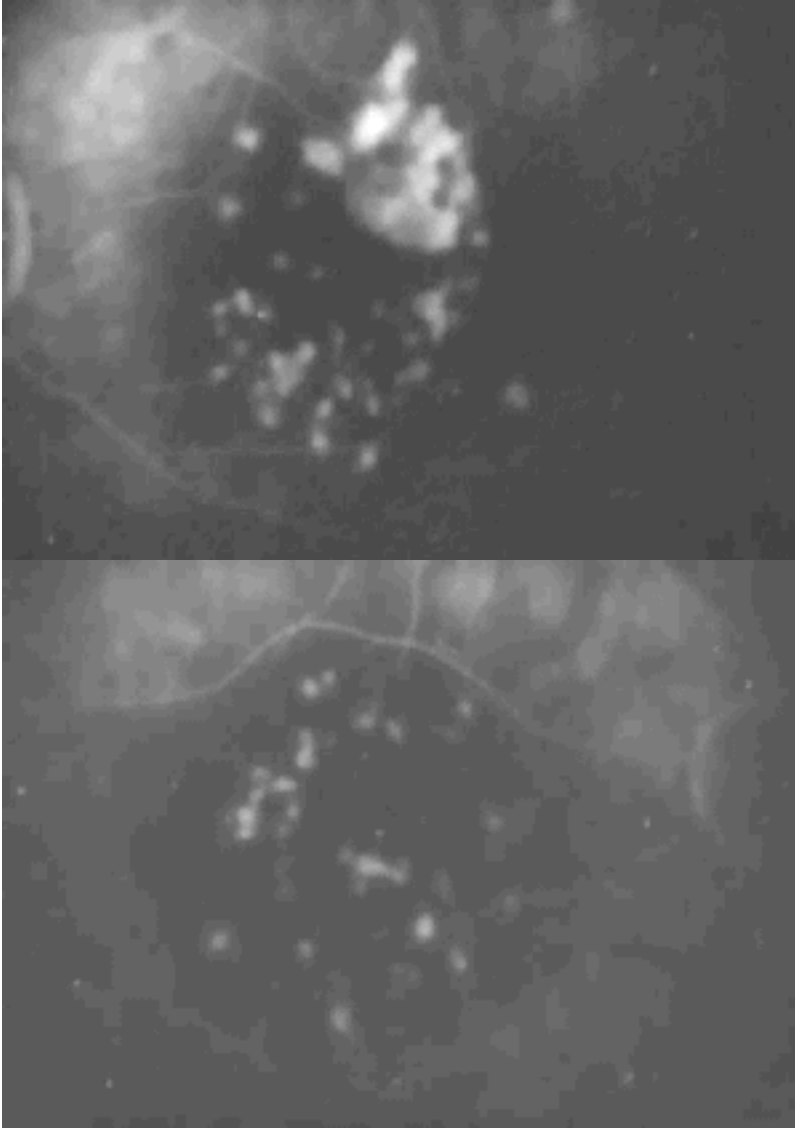
Amsler grid - Paracentral Scotomas OU

SLE - within normal limits OU

IOP - 16 OD, 14 OS

Fundi and FA





Discussion

Punctate inner choroiditis (PIC) was first described by Watzke in 1984 when he published an article in AJO describing 10 patients with what he thought was a unique entity. In his study there were 10 patients, all female who were myopic and otherwise healthy. They had bilateral yellow inner choroidal lesions in the posterior pole. They did not have any anterior chamber or vitreous cells and there were no associated medical condition was evident from the work up. 5 of 10 patients developed subretinal neovascularization (SRNV) but 8 of 10 retained 20/60 or better vision.

Clinical Features

There are 50 published cases of PIC. Among these cases F:M ratio is 49 to 1. Age of presentation ranged from 16 to 41. Common initial symptoms are blurry central vision, scotomas, and photopsia. No associated medical condition is identified. There frequently was associated serous retinal detachment over the choroidal lesions. 65 eyes in the literature had refractive correction recorded and it ranged from +1.00 to +14.00 with mean of +4.50 diopter. Fundus of patients with PIC discloses yellow white inflammatory lesions throughout the posterior pole. These lesions range in size from 100 to 300 microns. These lesions are present bilaterally in about 80% of the patients, but most of the time they are asymmetric. There is no iritis or vitritis

associated with PIC. FA shows that the active lesions are hyperfluorescent in the early phase and the late phase shows staining of the lesions.

25 to 60 % of patients with PIC developed subretinal neovascularization. The neovasculation develops through breaks in the Bruch's membrane, which results from the inner choroiditis. This is a sight threatening sequelae of PIC. ICG of fundus of patients with PIC shows areas of hypofluorescence corresponding to the choroiditis and if present, SRNV will show staining in the late phase.

Advanced stage of the disease manifests as subretinal fibrosis. It is associated with poor vision. Furthermore, subretinal fibrosis carries a poor prognosis, even with surgical removal, because the RPE in the area is severely damaged already.

Formal visual field testing may disclose enlarged blind spot. This may be due to the clustering of the lesions in the peripapillary region. ERG and EOG are generally within normal limits, however Brown and Folk observed that they tend to be significantly asymmetric.

Differential

Diagnosis

There are many entities that present as a "white dot syndrome." Frequently, they appear very similar, and the differentiation can be difficult. It is very important to differentiate multifocal choroiditis and panuveitis (MCP) from PIC, because the management is significantly different. MCP requires immunomodulation. The difference is the presence of vitritis and/or iritis in patients with MCP. Presumed ocular histoplasmosis (POHS), which presents with multifocal chorioretinal scars in the posterior pole and SRNV, can be differentiated by histoplasmin complement fixation tests, but more efficiently, the difference is that in POHS, SRNV is associated with inactive CRS. Patients with PIC have active choroidal lesions with SRNV when the vision deteriorates. Acute posterior multifocal placoid pigment epitheliopathy (APMPPE) is differentiated by the level of the lesions, which is slightly more superficial than those in PIC. On FA, APMPPE shows characteristic early hypofluorescence of the lesions in contrast to the hyperfluorescent lesions in PIC. Furthermore, SRNV is a rare complication of APMPPE.

Diffuse subretinal fibrosis (DSF) syndrome can mimic advanced stage of PIC. The difference is that in DSF, the course is much more rapidly progressive and carries a worse prognosis. Birdshot choroidopathy presents with peripheral lesions. Multiple evanescent white dot syndrome presents with lesions at the level of RPE. Usually they resolve and don't leave any scars or SRNV, unlike PIC.

Treatment

Active PIC lesions have shown response to oral and regional corticosteroids. There is even one report from England that oral steroids in PIC with SRNV can stabilize vision and reduce NV leakage. Serial ICG to survey for SRNV is recommended, since it is associated with irreversible vision loss in PIC. Prompt treatment of SRNV is effective, as demonstrated by our case. Surgical excision of the neovascular membrane has been performed with favorable results when the lesion membrane is subfoveal and laser photocoagulation carries a significant risk. When the membrane becomes fibrotic, the success rate diminishes. There is no report of benefit from immunomodulation in the literature. Thalidomide has been used without success in the treatment of SRNV. There is no report of PDT in SRNV associated with PIC.

Prognosis

Prognosis for patients with PIC can be good if diagnosis is made in a timely fashion and appropriate treatment and monitoring are initiated. Poor vision is associated with choroidal lesion in the fovea, development of SRNV, and development of subretinal fibrosis.

Summary

In summary, punctate inner choroiditis presents with bilateral inflammatory choroidal lesions of the posterior pole. It occurs mostly in young, myopic, otherwise healthy women. The diagnosis can be difficult because many other entities have similar appearance. The active choroidal lesions can be treated with oral and regional steroids. Patients should be monitored frequently for

SRNV with ICG. Generally PIC carries a good visual prognosis when the diagnosis and treatment are carried out appropriately.

References

- 1: Akman A, Kadayifcilar S, Aydin P. Indocyanine green angiographic findings in a case of punctate inner choroidopathy. *Eur J Ophthalmol.* 1998 Jul-Sep;8(3):191-4.
- 2: Brown J Jr, Folk JC. Current controversies in the white dot syndromes. Multifocal choroiditis, punctate inner choroidopathy, and the diffuse subretinal fibrosis syndrome. *Ocul Immunol Inflamm.* 1998 Jun;6(2):125-7.
- 3: Flaxel CJ, Owens SL, Mulholland B, Schwartz SD, Gregor ZJ. The use of corticosteroids for choroidal neovascularisation in young patients. *Eye.* 1998;12 (Pt 2):266-72.
- 4: Olsen TW, Capone A Jr, Sternberg P Jr, Grossniklaus HE, Martin DF, Aaberg TM Sr. Subfoveal choroidal neovascularization in punctate inner choroidopathy. Surgical management and pathologic findings. *Ophthalmology.* 1996 Dec;103(12):2061-9.
- 5: Ip M, Gorin MB. Recurrence of a choroidal neovascular membrane in a patient with punctate inner choroidopathy treated with daily doses of thalidomide. *Am J Ophthalmol.* 1996 Oct;122(4):594-5.
- 6: Brown J Jr, Folk JC, Reddy CV, Kimura AE. Visual prognosis of multifocal choroiditis, punctate inner choroidopathy, and the diffuse subretinal fibrosis syndrome. *Ophthalmology.* 1996 Jul;103(7):1100-5.
- 7: Reddy CV, Brown J Jr, Folk JC, Kimura AE, Gupta S, Walker J. Enlarged blind spots in chorioretinal inflammatory disorders. *Ophthalmology.* 1996 Apr;103(4):606-17.
- 8: Tiffin PA, Maini R, Roxburgh ST, Ellingford A. Indocyanine green angiography in a case of punctate inner choroidopathy. *Br J Ophthalmol.* 1996 Jan;80(1):90-1.
- 9: Adelberg DA, Del Priore LV, Kaplan HJ. Surgery for subfoveal membranes in myopia, angioid streaks, and other disorders. *Retina.* 1995;15(3):198-205.
- 10: Eldem B, Sener C. Punctate inner choroidopathy and its differential diagnosis. *Ann Ophthalmol.* 1991 Apr;23(4):153-5.
- 11: Watzke RC, Packer AJ, Folk JC, Benson WE, Burgess D, Ober RR. Punctate inner choroidopathy. *Am J Ophthalmol.* 1984 Nov;98(5):572-84.

Punctate Inner Choroiditis

David Chu, M.D.

1. Which of the following is not associated with PIC?
 - a. Serous retinal detachment
 - b. Female sex
 - c. Myopia
 - d. Vitreous cells
2. Which of the following description characterizes fluorescein angiographic findings of active PIC lesions?
 - a. Early hypofluorescence, late staining
 - b. Early hyperfluorescence, late staining

c. Early hypofluorescence, late hypofluorescence

d. None of the above

3. Which of the following diagnostic tests is most likely to be helpful in PIC?

a. Fluorescein angiogram

b. Electro-retinogram

c. Electro-oculogram

d. B-Scan

4. The following statements describe subretinal fibrosis in PIC except

a. RPE is likely damaged

b. Visual prognosis is good with surgery

c. It is a late manifestation of PIC

d. It occurs as a sequela of subretinal neovascularization

5. The following methods are used in treatment of PIC except

a. Systemic prednisone

b. Immunomodulation

c. Regional steroid

d. Subretinal surgery

True or False

6. Serial ICG is an appropriate way to monitor PIC.

7. PIC may differ from multifocal choroiditis and panuveitis by the lack of vitreous cells in PIC.

8. PIC generally carries a good prognosis even without treatment.

9. Subretinal neovascularization is a rare complication of PIC.

10. PIC usually has symmetric presentation.

1.d, 2. b, 3. a, 4. b, 5. b, 6. True, 7. True, 8. False, 9. False, 10. False

