

Choroidal Neovascularization in Sympathetic Ophthalmia

Lucia Sobrin, Miguel Cordero Coma, C. Stephen Foster

Case Report

A 49-year-old man presented after a ruptured globe repair of his left eye status post a bungee cord injury with decreased vision in his right eye six weeks after the trauma occurred. Visual acuities were 20/40 in the right eye and no light perception in the left eye. Intraocular pressures were 27 and 5, respectively. Slit lamp examination of the right eye revealed 1+ conjunctival injection, fine keratic precipitates and 1+ anterior chamber cells. Examination of the left eye revealed a sutured corneal laceration with no view of the iris or lens. Fundus examination and fluorescein angiography of the right eye revealed papillitis, vasculitis and peripheral choroidal lesions consistent with Dalen-Fuchs nodules. He was diagnosed with sympathetic ophthalmia. He underwent enucleation of the left eye and was started on Pred Forte therapy, Prednisone and CellCept. He failed CellCept therapy and eventually was started on Leukeran.

His vision was stable for several months on Leukeran before noticing a sudden drop in vision in the right eye. The vision was measured as 20/100. His slit lamp exam showed no inflammation. His dilated exam showed subfoveal hemorrhage and fluid (Figure 1).

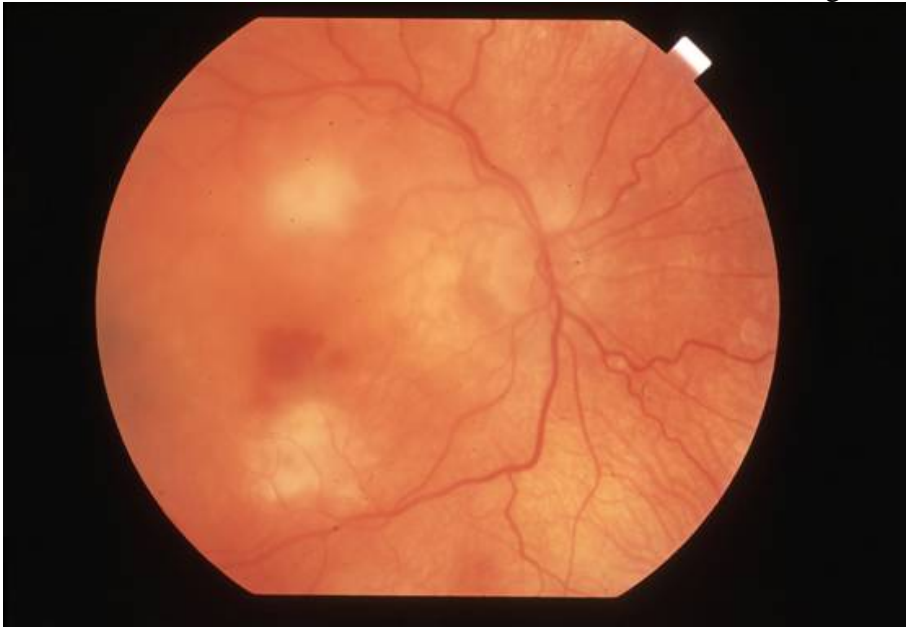

Figure 1

A fluorescein angiogram revealed a subfoveal neovascular membrane (Figure 2).

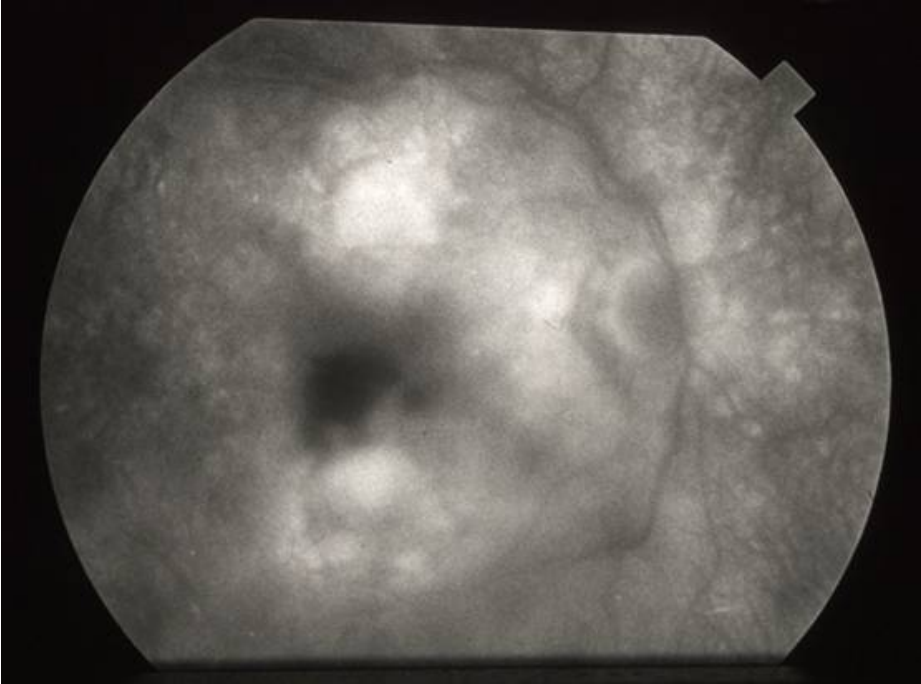


Figure 2

He underwent two intravitreal Macugen injections with improvement of his vision to 20/40 and resolution of the hemorrhage and fluid (Figure 3).

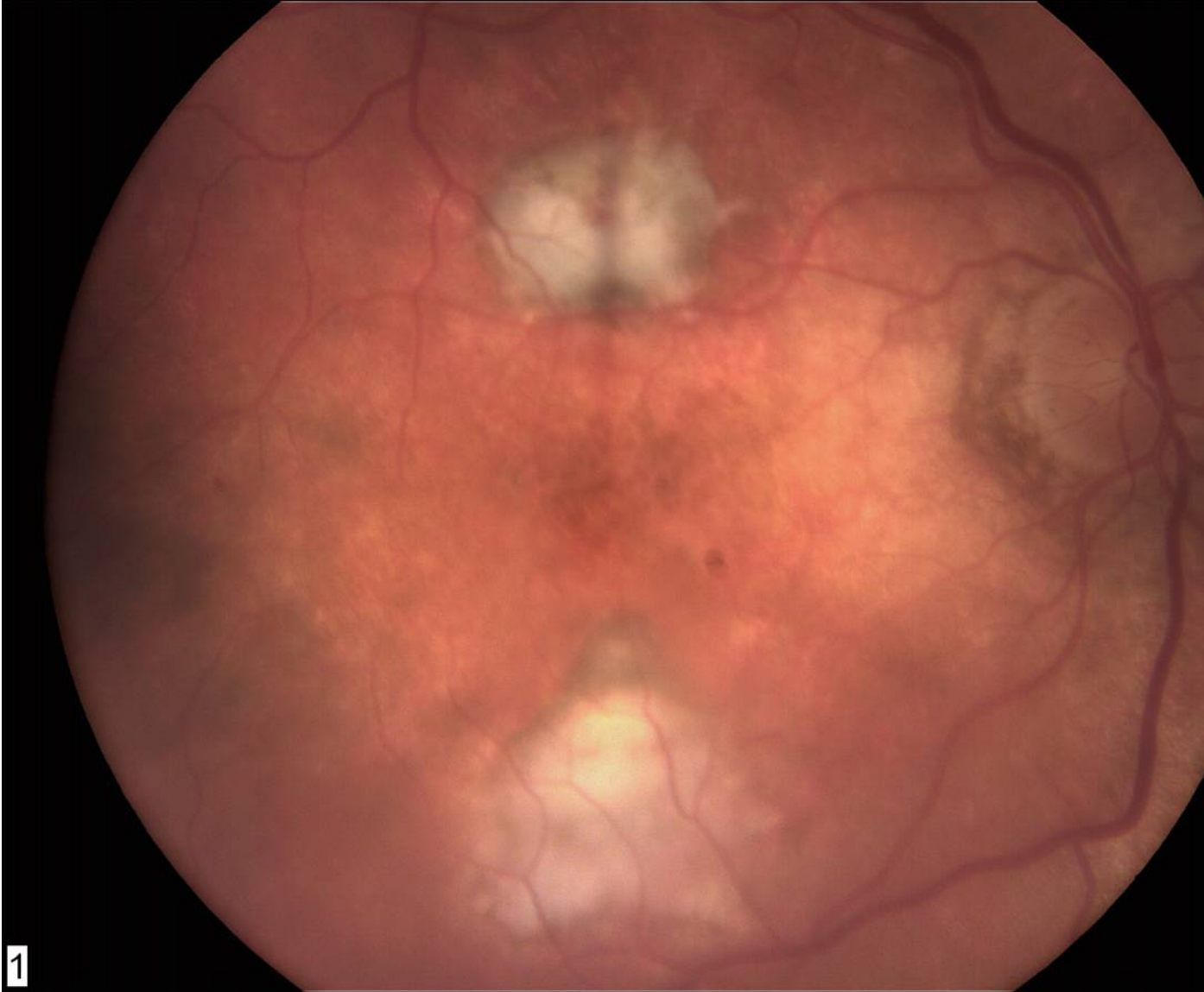

Figure 3

His angiogram showed no active neovascularization.

Sympathetic Ophthalmia

SO is a bilateral, granulomatous panuveitis that occurs after penetrating trauma to one eye. Both the injured eye (called the *exciting* eye) and the fellow one (called the *sympathizing* eye) are involved. The time from ocular trauma to onset of SO ranges from 10 days to 66 years, but 80% of cases occur within 3 months and 90% occur within one year of the trauma.

The overall incidence is 0.2% to 0.5 % after penetrating trauma and 0.01% after ophthalmologic procedures. It has been associated with a wide variety of ophthalmic procedures, from pars plana vitrectomy, cataract extraction, and evisceration to less

invasive interventions such as a paracentesis. SO should be considered in any uveitis occurring after ocular surgery, particularly after multiple vitreoretinal surgeries.

Clinical Features and Diagnosis

The diagnosis of SO is based on both the history and clinical findings. Therefore, a detailed history and exam is crucial to a prompt diagnosis. SO often presents as a bilateral panuveitis. The patient's complaints range from mild visual disturbance to severe visual loss. Other common presenting symptoms reported are photopsias, floaters and photophobia. The most common ocular findings in the anterior chamber are mutton fat keratic precipitates and variable degrees of inflammatory reaction. The iris may also be thickened and could contain nodules similar to those seen in other granulomatous entities. The posterior segment involvement is the most characteristic and may include vitreous cells, retinal vasculitis, papillitis, choroiditis, and serous retinal detachment. The most classic findings, though not pathognomonic, are whitish-yellowish infiltrates which are usually seen in the peripheral choroid and are named Dalen-Fuchs nodules. They are seen in about one third of patients with SO.

As in other chronic uveitides, persistent inflammation can result in a wide spectrum of complications such as cataract, secondary glaucoma, retinal and optic nerve atrophy (with or without retinal detachment and subretinal fibrosis), choroidal neovascularization and pthisis bulbi.

The fluorescein angiogram is a useful test, especially in the acute phase of the SO, showing diffuse areas of fluorescein leak that may correspond to Dalen-Fuchs nodules. There is often late staining of the optic nerve. Indocyanine green angiography could also be helpful, especially if there is choroidal neovascularization.

The differential diagnosis of SO includes other panuveitides, especially the granulomatous ones. Vogt- Koyanagi-Harada syndrome (VKH) often has a similar presentation, but there are some important differences such as lack of surgery or ocular penetrating injury history and more common associated systemic findings (skin changes, CSF pleocytosis, hearing dysfunction, CNS findings) Choriocapillaris involvement and predisposition in more darkly pigmented races also helps to distinguish between these two entities.

Etiology

SO is an autoimmune inflammatory reaction that occurs in the eye. The identity of the specific inciting antigen within the eye is unclear. Several antigens has been implicated, such as retinal S-antigen, interphotoreceptor retinoid binding protein (IRBP), melanin containing tissue, and other antigens derived from the retinal pigment epithelium and choroid. Various experimental models of SO can be created by injection of some of the aforementioned antigens into animals' eyes.

Interestingly, however, there are frequent situations, such as glaucoma filtering surgery, in which uveal tissue is chronically exposed to the conjunctival lymphatics, without causing SO. On the other hand, non-penetrating ophthalmic procedures have been related with this disease. It is clear that there is still much to learn about the pathogenesis of SO. There is some work that suggests the presence of certain demonstrated adjuvants, such as microbe components, may be partially responsible for generating the inflammatory condition that we know as SO.

Histopathology

The basic finding in the histopathological study of eyes with SO is a diffuse non-necrotizing granulomatous inflammation throughout the uveal tissue, except for the choriocapillaris. The inflammatory cells include T-helper lymphocytes in the early phases and suppressor cytotoxic lymphocytes later in disease. Epithelioid cells and multinucleated giant cells are commonly seen. Dalen-Fuchs nodules' histopathology deserves special mention. These represent clumps of lymphocytes and epithelioid cells anterior to Bruch's membrane.

Management

To the best of our knowledge, the sole prophylactic, well-documented option to prevent SO is uveal excision surgery prior to the beginning of the inflammatory response. The shortest well documented, both clinically and histopathologically, interval between the injury/surgery and appearance of SO is 10 days. Of note, the minimum time for the development of a delayed hypersensitivity response after antigen exposure is also ten days. Both the informed patient and the surgeon have to make this decision cautiously, considering that sometimes the exciting eye is the one with the best vision when the disease is under control.

Whether enucleation or evisceration is a better option remains controversial. There are several case reports demonstrating development of this pathology in the fellow eye following evisceration, but none of these have been published in the last 30 years despite the fact more eviscerations for SO have probably been performed in recent decades. Also given the already-present history of ocular injuries or surgery, it is impossible to definitively determine that evisceration was responsible for SO in these cases. An increasing number of surgeons decide to perform evisceration based on its superior results in terms of long-term cosmetic outcome compared to enucleation. Late enucleation or evisceration (after development of SO) is currently not recommended if the eye has any functional vision.

The first step before starting immunosuppressive treatment is to rule-out an infectious agent, either local or systemic, as the cause of the inflammation. This is particularly important in these patients who have a history of a recent ocular injury or procedure. Once infection is excluded, there is a general agreement that immunosuppressive therapy is necessary for achieving a good final visual acuity in eyes affected by this entity.

The initial treatment of SO is with systemic corticosteroids. Oral prednisone (1 - 1.5 mg/kg/day) is the usual agent chosen, although others such as methylprednisolone could be used intravenously in a short pulse of three days followed by the usual dosage of oral prednisone. Because SO is an inflammatory entity that affects the eye but comes from a systemic immune response against an ocular antigen, oral or intravenous administration is probably the most appropriate route, although topical and regional (sub-Tenon's) steroids could be also used as adjuvants to the systemic treatment. The estimated time to verify the response to steroids is variable, and signs of active inflammation (anterior and posterior chamber cells, choroiditis) have to decrease gradually before considering a slow taper of the corticosteroid dosage.

Unfortunately, the long term use of steroids has many potential undesirable adverse effects. This reality, in addition to the possibility of persistent inflammation despite corticosteroid treatment, creates the need for other immunosuppressive agents.^{1,2} Oral cyclosporine, with or without systemic steroids, has been reported as an alternative regimen in steroid-resistant cases of SO and has different degrees of success. The dosage of cyclosporine and average time in remission necessary to discontinue the treatment varies. Another interesting agent that has been used is chlorambucil (Leukeran). It has been especially effective in forms of SO that are recalcitrant to conventional therapy. Its major side effect is bone marrow depression that has to be carefully managed because it is precisely when low white blood cell counts are achieved that there is a higher chance for success in prevailing over the inflammation in the short- and long-term. Finally other immunomodulatory treatments, alone or combined, including methotrexate, mycophenolate mofetil, azathioprine and tacrolimus, have been reported. In terms of secondary prevention, it is important to consider adequate immunomodulatory therapy if further ophthalmic procedures are required.

Choroidal Neovascularization in SO

Chronic choroidal inflammation in SO can lead to a defect in Bruch's membrane. This can lead to growth of choroidal neovascularization through the defect in Bruch's membrane into the subretinal space. Sometimes neovascularization is seen to arise from under a Dalen-Fuchs nodule. Various treatments, including laser photocoagulation, photodynamic therapy, and surgical excision, have been reported.³⁻⁵ Spontaneous resolution while on cyclosporine therapy has also been reported.⁶

Macugen (pegaptanib sodium) is an anti-vascular endothelial growth factor (VEGF) aptamer that binds VEGF165 in the eye. It has been approved in the United States for treatment of choroidal neovascularization secondary to age-related macular degeneration. In the clinical trials of Macugen, 70% of treated patients compared with 55% of control patients had loss of less than 15 letters of vision. Avastin (bevacizumab), another anti-VEGF therapy, has also been used on an off-label basis to treat choroidal neovascularization.

References

1. Yang C-S et al. Chlorambucil therapy in sympathetic ophthalmia. *Am J Ophthalmol* 1995; 119: 482 – 8.
2. Chan C-C et al. 32 cases of sympathetic ophthalmia: a retrospective study at the National Eye Institute, Bethesda, MD from 1982 to 1992. *Arch Ophthalmol* 1993; 113; 597 – 600.
3. Borkowski LM et al. Laser photocoagulation for choroidal neovascularization associated with sympathetic ophthalmia. *Am J Ophthalmol* 2001; 132: 585 - 87.
4. Kinge B et al. Photodynamic therapy for choroidal neovascularization secondary to sympathetic ophthalmia. *Retina* 2005; 25: 375 – 77.
5. Bom S et al. Surgery for choroidal neovascularization in sympathetic ophthalmia. *Retina* 2001; 22: 109 – 11.
6. Kilmartin DJ et al. Cyclosporine-induced resolution of choroidal neovascularization associated with sympathetic ophthalmia. *Arch Ophthalmol* 1998; 116: 249 – 50.

Figure Legends

Figure 1. Subretinal hemorrhage just superior to an area of subretinal fibrosis in the right eye.

Figure 2. Late phase of the fluorescein angiogram reveals blockage from the hemorrhage with adjacent fluorescein leakage.

Figure 3. After two Macugen injections, the subretinal hemorrhage and fluid have resolved. A subretinal pigmented fibrotic scar is seen at the superior edge of the subretinal fibrosis mound inferior to the fovea.