

# Dengue Chorioretinitis and Dengue-Related Ophthalmic Complications

## The Eye Institute Dengue-Related Ophthalmic Complications Workgroup

**Dr. Stephen C B TEOH<sup>1</sup>**  
**MMed(Ophth), FRCSEd(UK)**  
*Stephen\_Teoh@ttsh.com.sg*

Dr. Caroline K L CHEE<sup>2</sup>  
MMed(Ophth), FRCSEd(Ophth)

Dr. David P L CHAN<sup>1</sup>  
MMed(Ophth), MRCSEd(UK)

Dr. Tock H LIM<sup>1</sup>  
MMed(Ophth), FRCSEd(Ophth)

Dr Augustinus LAUDE<sup>1</sup>  
MMed(Ophth), MRCSEd(UK)

Dr. Kong Y GOH<sup>1</sup>  
FRCSEd(Ophth)

<sup>1</sup>The Eye Institute @ Tan Tock Seng Hospital  
11 Jalan Tan Tock Seng  
Singapore 308433  
Republic of Singapore

<sup>2</sup>Department of Ophthalmology  
National University Hospital  
5 Lower Kent Ridge Road  
Singapore 119074

### **Case Report #1**

A 32-year old woman was diagnosed with dengue fever by her GP on day 4 of her febrile illness. Blood investigations showed progressive thrombocytopenia and was positive for dengue virus on polymerase chain reaction (PCR) analysis. On day 7 after onset of fever, she noticed sudden painless bilateral blurring of vision upon waking. Platelet count was at its nadir of  $26 \times 10^9/L$ . Visual acuity were 20/400 and counting fingers 1 foot in the right and left eyes respectively. External and slit lamp examinations were unremarkable and intraocular pressures were within normal limits. Dilated fundi examination revealed focal macular chorioretinitis with macular edema associated with vasculitis and flame hemorrhage. Fundus fluorescein angiography revealed extensive periphlebitis in both eyes (Fig 1).

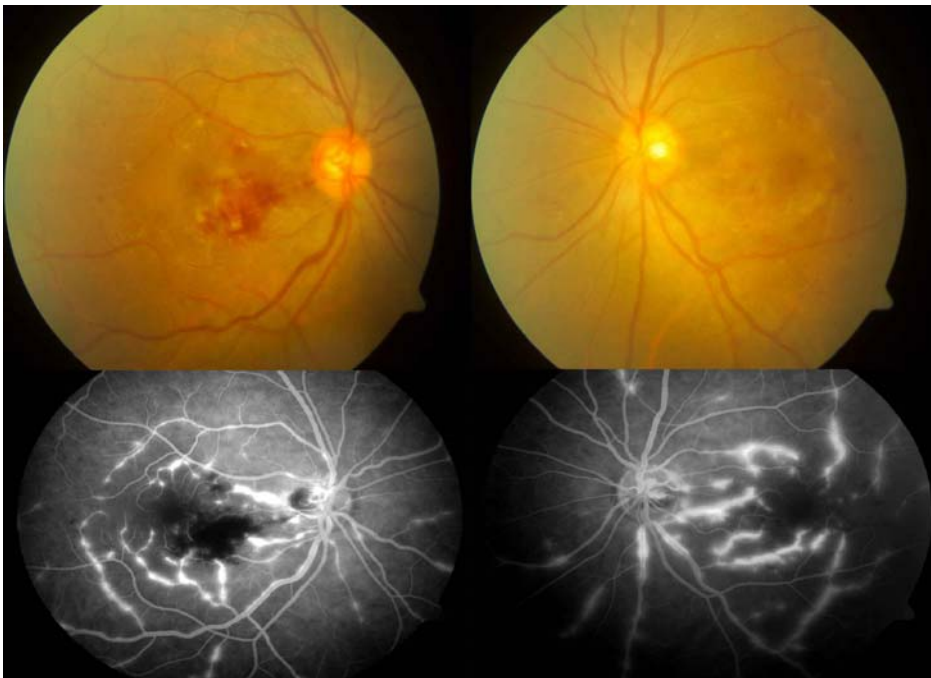
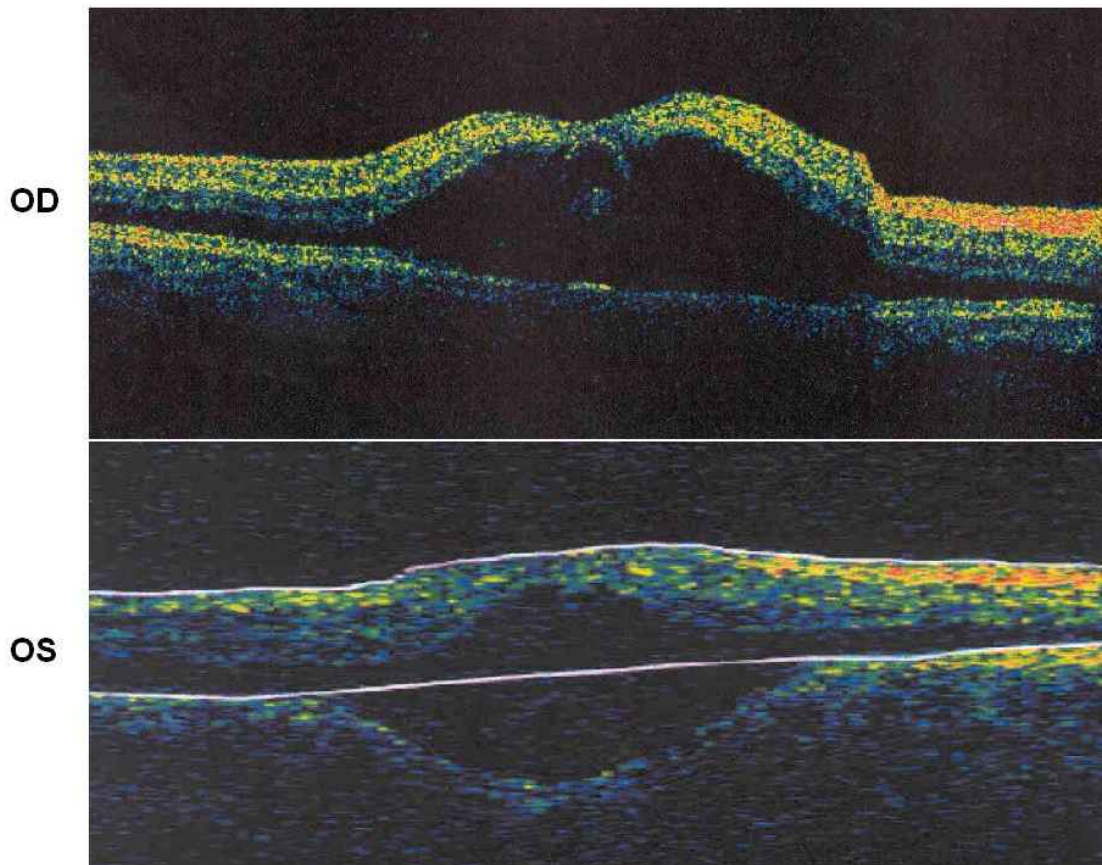


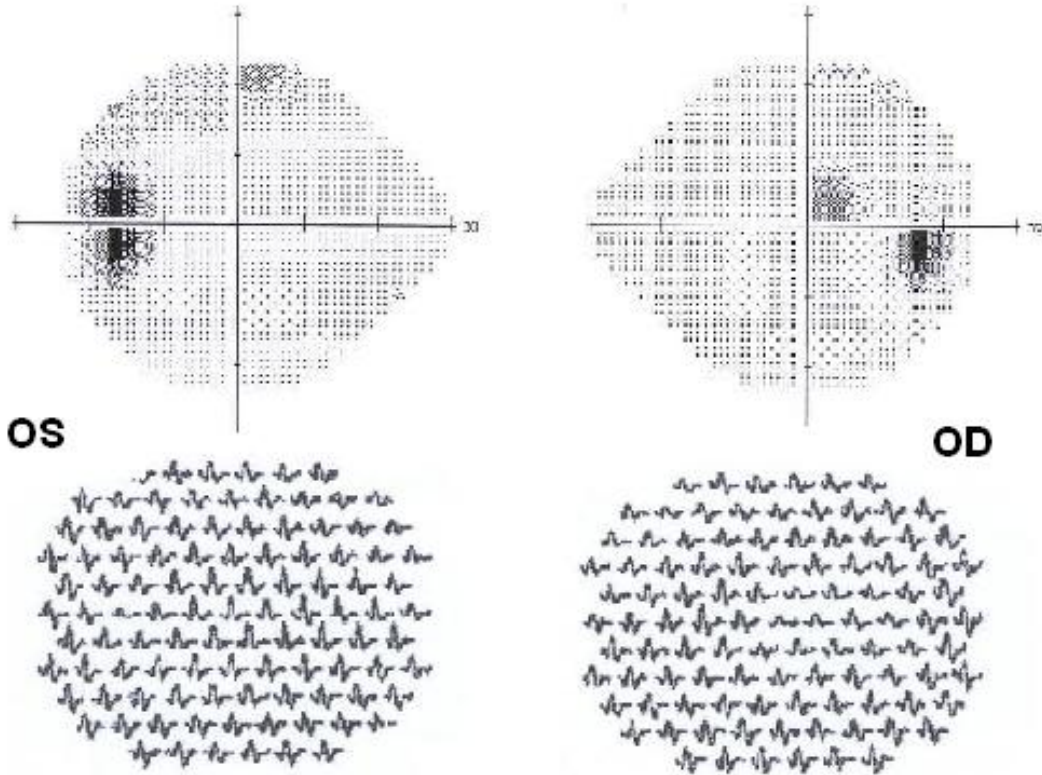
Figure1

*A diagnosis of dengue-related chorioretinitis with maculopathy was made. She recovered spontaneously with full anatomic resolution over the next three months without specific treatment. However she retained relative paracentral scotomata (Fig 2)*



*Figure 2*

worse in the right eye that was clearly demonstrable on multifocal electroretinography (Fig 3).



## **Case Report #2**

*A 20-year old man was diagnosed with dengue fever 4 days after onset of a febrile illness. Blood PCR and IgM were positive for dengue. He complained of right non-specific visual disturbance and a left paracentral relative scotoma associated with floaters on day 7 of his illness. His serial platelet counts were  $65 \times 10^9/L$  (nadir on day 6) and  $123 \times 10^9/L$  (day 7). Visual acuities were 20/20 with normal intraocular pressures. There was no activity in the anterior segments but there was 1+ vitritis in the left eye. Fundus examination showed a small focal area of choroiditis in the peripapillary macula bundle. Fluorescein and indocyanine green angiography were normal. The clinical impression was dengue choroiditis. He was treated with oral prednisone 1mg/kg and a rapid taper with good initial improvement of symptoms. He had a relapse of left scotoma at 20mg prednisone that required dose increment followed by a slow taper of 10mg/wk with no subsequent relapses. The scotoma resolved after 6 months.*

### **Case Report #3**

*A 27-year old man was admitted for worsening thrombocytopenia following diagnosis of dengue fever. His dengue IgM was positive. Serial platelet counts were  $55 \times 10^9/L$  (nadir on day 6) and  $85 \times 10^9/L$  (day 7). On the morning of day 7, he complained of bilateral central scotomas. Visual acuities were 20/20 and 20/400 in the right and left eyes respectively. There was 2+ anterior chamber activity in the left eye and a small focal chorioretinitis in both maculae evident on fluorescein angiography, more in the left. Indocyanine angiography and OCT were normal. He was treated with oral prednisone 1mg/kg with a slow taper of 10mg/wk. The choroiditis and vasculitis resolved with no complications but his scotoma resolved only after 6 months.*

### **Case Report #4**

*A 40-year old man with previous refractive surgery complained of blurring of vision in both eyes, worse in the left on day 7 of a febrile illness that was diagnosed to be dengue fever based on a positive dengue IgM. Visual acuities were 20/40 and 20/200 in the right and left eyes respectively. There was a left relative afferent papillary defect with impaired color vision. Anterior segments were quiet. Fundus biomicroscopy examination showed normal discs with bilateral mild macular edema but fluorescein and indocyanine green angiographies were normal. The clinical impression was that of dengue-related optic neuritis with maculopathy. He was treated with intravenous pulsed methylprednisolone 1g for 3 days followed by a tapering course of oral*

*prednisone 1mg/kg. Visual acuity improved with resolution of macula edema. At 6 months, visual acuity were 20/30 and 20/60 respectively still with impaired color vision in the left eye on Ishihara plate assessment and a relative paracentral scotoma.*

### **Background and Epidemiology**

Dengue fever (DF) and dengue hemorrhagic fever (DHF) are the most prevalent form of flavivirus infection in humans. Infection is caused by the dengue virus, of which there are four closely-related but antigenically distinct serotypes that do not confer cross-immunity: DEN-1, -2, -3 and -4. As such, individuals in endemic countries are not protected from the other serotypes after infection with one serotype. Borne by the *Aedes* mosquito, this is primarily a disease of the tropics and subtropics, and of urban development. The spectrum of disease presentation may range from mild febrile illness to a severe potentially life-threatening hemorrhagic infection, especially in children under 15 years and in patients who have had previous infections. Since the 18<sup>th</sup> century, there have been documented epidemics occurring periodically with increasing frequency and resurgences in the last 50 years due to increased air travel and urbanization. Based on WHO estimates, there are tens of millions of cases of DF and up to hundreds of thousands of cases of DHF annually with a case-fatality rate of DHF ranging from 5% to less than 1% in modern facilities with proper and prompt supportive treatment.<sup>1-2</sup>

## **Definition**

DHF is defined by the World Health Organisation (WHO) as dengue fever associated with thrombocytopenia ( $<100 \times 10^9$  cells/L) and hemoconcentration (hematocrit elevated  $>20\%$  above baseline). Dengue shock syndrome (DSS), the most severe form of the disease, is associated with hypotension, narrowing of pulse pressure ( $<20$ mmHg) and circulatory failure in 30% of cases. The mortality rate for untreated DHF/DSS can be as high as 10-15% in places where patients have no ready access to emergency supportive treatment with intravenous fluids and platelet replacement.<sup>2</sup>

## **Disease Spectrum**

Systemic dengue infection presents most commonly with dengue fever, a self-limiting illness characterized by pyrexia, headache, retro-orbital pain, joint pains and petechial rash due to thrombocytopenia. Signs and symptoms typically resolve after about one week with recovery of platelet counts. Unlike DF, DHF and DSS are potentially fatal forms of the illness classically ascribed to sequential infections with certain serotypes of dengue viruses by a process of immune enhancement.<sup>3</sup> However, this association between secondary infection and/or co-circulation of different dengue serotypes has not been consistently observed<sup>4</sup> and has been thought to be multi-factorial including high viremia titre and infection with specific serotypes with higher viral virulence, increased pathogenicity or greater immunological responses.<sup>5,6</sup> This has been especially associated with DEN-1, -2 and -3 serotypes.<sup>6-9</sup>



## **Diagnosis of Dengue Infection**

Dengue fever is a viral pyrexial illness characterized clinically by abrupt onset of high fever (up to 39 – 41°C) that lasts for 2 – 7 days then resolves in 2 – 3 days accompanied by a characteristic transient, generalized petechial rash and ache including bone pain, frontal and retroorbital pain. Diagnosis can be made on clinical grounds by the constellation of above symptoms, signs and thrombocytopenia in endemic countries but unequivocal diagnosis of dengue infection requires laboratory confirmation by detection of the virus via specific antibodies (dengue IgG, IgM) or polymerase chain reaction (PCR) detection of dengue RNA. Serum specimens should be collected as soon as possible within 5 days after onset of symptoms. For serologic diagnosis, a positive Dengue IgM is highly suggestive, but a convalescent-phase serum specimen should be obtained about 6 days after onset of symptoms. Serological tests that have been used include: hemagglutination-inhibition (HI), complement fixation (CF), neutralization test (NT), immunoglobulin M (IgM) capture enzyme linked immunosorbent assay (MAC-ELISA) and indirect immunoglobulin G ELISA. Although the ELISA tests are the most common techniques utilized for serological diagnosis, these tests are limited by their high cross-reactivity. In recent times, newer molecular diagnostic techniques have been developed and have proven very useful in dengue diagnosis. Dengue (RT)-PCR has been widely utilized in many centers and has proved to be a useful tool for rapid and early detection of dengue infection as well as serotype analysis – a distinct advantage

compared to ELISA tests. It has also been shown to be able to detect dengue viruses up to the 10th day after the onset of the symptoms.<sup>10</sup>

### **Ocular Clinical Characteristics in Dengue Infection**

Ophthalmic complications were not typically reported in dengue infections. The most common reported complications are subconjunctival hemorrhage secondary to a bleeding diathesis from thrombocytopenia and non-specific retro-orbital pain. First described in 1979,<sup>11</sup> isolated case reports of dengue-related retinal hemorrhages and maculopathy have been published in the English literature among tourists who have returned from dengue-endemic countries. However since 2000, dengue-related chorioretinitis and ocular inflammation have been increasingly reported especially from South-East Asia.<sup>12</sup> Chan *et al* described a series of 13 patients occurring in Singapore over 6 months.<sup>13</sup> There have been more reports of similar occurrences published since then.<sup>14,15</sup>

The most common ocular manifestation in immunocompetent individuals is an inflammatory maculopathy comprising focal chorioretinitis with or without macular edema. Optical coherence tomography (OCT) often demonstrates macular edema with foveal elevation that usually resolves rapidly over 1 – 5 days. Additional ocular findings may include retinal hemorrhages, retinal vasculitis (periphlebitis), vitritis, anterior uveitis, intermediate uveitis and uncommonly, optic neuritis or papillitis. Laude *et al* and Chan *et al*, from The Eye Institute published 2 articles in the infectious disease journal of CDC (Atlanta), Emerging Infectious

Diseases, in 2005 and 2006 on a series of patients who presented with these emerging complications.<sup>13,16</sup> Chan described the typical course of the disease. Patients who present with ocular inflammatory complications tended to be younger (mean age 31.7 years) with no gender predilection. Cases typically present around day 7 (mean 6.8 days, range 5-8) after the onset of the fever, similar to a series by Wen *et al* (mean 7.26 days, range 2-15 days). This correlates with the nadir of thrombocytopenia – just before recovery of the platelet count. Majority of cases are acute and bilateral (75%) and patients complained of blurring of vision or visual scotomata, and less commonly floaters or non-specific visual disturbance.

The common symptoms presented by patients include:

Blurring of vision	58%
Central scotoma	27%
Micropsia / Metamorphopsia	3.6%
Visual field defect	1.8%
Floaters	5.5%
Near vision disturbance	5.5%
Redness	1.8%

Visual acuities range from 20/20 to counting fingers (10% worse than 20/200). Fluorescein angiography may be normal or in patients with posterior pole involvement, reveal characteristic changes of retinal vasculitis with or without disc leakage during the acute phase of the disease. Perifoveal arteriolar hyperfluorescence have also been reported. Indocyanine green angiography may disclose areas of early diffuse hyperfluorescence of the choroidal vessels.<sup>12</sup> Electrophysiology assessment in patients with maculopathy may show depressed areas of response on multifocal electroretinography correlating to the areas of

scotoma consistent with areas of macular dysfunction. This feature can persist for months after clinical resolution. On follow-up, patients with maculopathy may develop dry perifoveal pigmentary changes after the initial episode of inflammatory chorioretinitis.

### **Pathogenesis**

The pathogenesis of ocular complications following dengue fever is as yet unknown. However, clinical presentation and behavior of these complications suggest an immunogenic etiology rather than an infective one. Patients manifest complications in varying degrees of severity around day 7 after the onset of their viral febrile illness. This is the time when most patients with uncomplicated disease are just about to recover both systemically as well as hematologically, and could correlate to the body's increasing immunologic response. Moreover their systemic and ocular conditions do not worsen and indeed appear to enhance recovery in some patients with systemic steroids.

It is probable that the pathogenesis of these ocular manifestations are directly related to the immunopathogenesis of dengue fever – a subject of ongoing research. Infection of cells with dengue virus has been postulated to cause a shift in balance of the cell-mediated immunity from Th1 and Th2 resulting in CD4/CD8 inversion and release proinflammatory mediators including IFN $\gamma$  and tumour necrosis factor (TNF)- $\alpha$  that can directly affect vascular endothelial cell apoptosis resulting in increased permeability. Autoantibodies against endothelial

cells and platelets as a result of increased interleukin (IL)-6 production or molecular mimicry against dengue virus structural proteins have also been reported. However, raised cytokine levels and autoantibodies alone cannot explain the manifestations seen as this is also a feature in many infective diseases that do not result increased vascular permeability.<sup>17-18</sup>

Other postulates include viral mutations, viral virulence and host susceptibility. Viral genetic mutations have been demonstrated to occur within the various serotypes, however the biologic effects induced by these mutations are as yet uncharacterized. It is possible that new mutations have resulted in a more virulent and proinflammatory strain or a strain with viral epitopes that mimic host structures. Although no clear association with human histocompatibility (HLA) haplotype has been reported, it has been suggested that viral non-structural proteins can block interferon  $\beta$  (IFN- $\beta$ ) and IFN- $\gamma$  production in vitro. The magnitude of individual T-cell activated responses directed against the infecting viral serotype has also been proposed to contribute to the severity of the disease. Current research is still preliminary and the evidence for these postulates is still very tenuous. More research is still needed to evaluate the pathogenesis of these ocular manifestations.<sup>18-21</sup>

### **Treatment**

There is no specific treatment for systemic dengue fever, DHF and DSS and management revolves around supportive therapy for the patient and any

complications such as fluid correction for electrolyte imbalance and hypotension, platelet transfusion for severe thrombocytopenia and management of shock. There are no specific anti-viral agents available. With appropriate supportive therapy and close monitoring, mortality from DHF and DSS can be significantly reduced.

The course of the ocular complications, like systemic DF, is generally self-limiting. Anatomical and structural resolution usually occurs within the first week with or without treatment with systemic immunosuppression. Serial OCT imaging will demonstrate a spontaneous rapid resolution of macular and foveal edema but functionally, patients may complain of persistent central or paracentral scotomata even up to months after resolution of the illness. This usually correlates with the severity of the initial presentation. Prognosis for central visual acuity is usually good with up to 85-90% regaining 20/30 or better. However in patients with severe maculopathy, final visual acuity may remain impaired (<20/40) or with impaired color vision in patients who present with inflammatory optic neuropathy. Clinically and on imaging, the presumed 'immune-mediated' lesions resolve rapidly, it is probable that the greatest injury occurs with the initial insult within the first few days leading to subsequent persistent scotoma and/or impaired vision or that subclinical inflammation exists resulting in long-term functional impairment. In view of this potential morbidity, use of systemic immunosuppression e.g. immediate high-dose steroids at presentation has been suggested and tried with varying success - to suppress and minimize the inflammatory damage followed

by rapid taper. Further randomized controlled studies coupled with a better understanding of the underlying pathophysiology will be necessary to evaluate the efficacy and success of this treatment.

### **Acknowledgements**

*We thank Mr. Ken Thian for the excellent photography and imaging of the patients as well as Dr. Audrey Chia from the Singapore Eye Research Institute Visual Electrophysiology Laboratory for assisting in the electrophysiology assessment.*

**Figure 1:** Color fundus photographs showing extensive vasculitis and foci of chorioretinitis especially around the macula, with correlating fluorescein angiography demonstrating periphlebitis throughout the retina.

**Figure 2:** OCT imaging of the maculae showing severe maculopathy with edema.

**Figure 3:** Automated visual fields of patient performed after 6 months after the initial presentation demonstrating residual paracentral scotoma especially in the right eye with correlating definite areas of decreased responses on the multifocal electroretinogram consistent with macular dysfunction.

### **References**

1. Halstead SB. Global epidemiology of dengue hemorrhagic fever. Southeast Asia J Trop Med Pub Health 1990;21:636.
2. Key issues in dengue vector control towards the operationalization of a global strategy: report of consultation. Geneva, World Health Organization:1995 (CTD/FIL(Den)/IC 96.1).
3. Halstead SB, O'Rourke EJ. Dengue viruses and mononuclear phagocytes. I. Infection enhancement by non-neutralizing antibody. J Exp Med. 1977;146:201–17.
4. Harris E, Videz E, Perez L et al. Clinical, epidemiologic, and virologic features of dengue in the 1998 epidemic in Nicaragua. Am J Trop Med Hyg 2000, 63:5-11.



5. Vaughn DW, Green S, Kalayanarooj S et al. Dengue viremia titer, antibody response pattern, and virus serotype correlate with disease severity. *J Infect Dis* 2000, 181:2-9.
6. Libraty DH, Endy TP, Houg HS et al. Differing influences of virus burden and immune activation on disease severity in secondary dengue-3 virus infections. *J Infect Dis* 2002, 185:1213-1221.
7. Corwin AL, Larasati RP, Bangs MJ et al. Epidemic dengue transmission in southern Sumatra, Indonesia. *Trans R Soc Trop Med Hyg* 2001, 95:257-265.
8. Guzman MG, Kouri G, Bravo J et al. Effect of age on outcome of secondary dengue 2 infections. *Int J Infect Dis* 2002, 6:118-124
9. Rico-Hesse R, Harrison LM, Salas RA et al. Origins of dengue type 2 viruses associated with increased pathogenicity in the Americas. *Virology* 1997, 230:244-251
10. De Paula SO, Fonseca BA. Dengue: a review of the laboratory tests a clinician must know to achieve a correct diagnosis. *Braz J Infect Dis*. 2004;8(6):390-8.
11. Deutman AF, Bos PJ. Macular bleeding in dengue fever. *Klin Monatsbl Augenheilkd* 1979; 175:429.
12. Lim WK, Mathur R, Koh A et al. Ocular manifestations of dengue fever. *Ophthalmology* 2004; 111:2057-64.

13. DPL Chan, SCB Teoh, CSH Tan et al. The Eye Institute Dengue-Related Ophthalmic Complications Workgroup: Ophthalmic Complications of Dengue. *Emerg Infect Dis* 2006;12(2):285-9.
14. Siqueira RC, Vitral NP, Campos WR, Orefice F, de Moraes Figueiredo LT. Ocular manifestations in Dengue fever. *Ocul Immunol Inflamm.* 2004;12(4):323-7.
15. Mehta S. Ocular lesions in severe dengue hemorrhagic fever (DHF). *J Assoc Physicians India.* 2005;53:656-7.
16. MP Chlebicki, B Ang, T Barkham, A Laude. Retinal hemorrhages in 4 patients with dengue fever. *Emerg Infect Dis* 2005;11(5):770-2.
17. Lei HY, Yeh TM, Liu HS et al. Immunopathogenesis of dengue virus infection. *J Biomed Sci* 2001;8:377-88.
18. J Stephenson. Understanding dengue pathogenesis: implications for vaccine design. *Bull WHO* 2005;83:308-14.
19. Lin CF, Chiu SC, Hsiao YL et al. Expression of cytokine, chemokine, and adhesion molecules during endothelial cell activation induced by antibodies against dengue virus nonstructural protein 1. *J Immunol.* 2005;174(1):395-403.
20. Y Nukui, S Tajima, A Kotaki et al. Novel Dengue virus type-1 from Travelers to Yap State, Micronesia. *Emerg Infect Dis* 2006 Feb;12(2):343-6.

21. Mokolsapaya J, Dejnirattisai W, Xu X et al. Original antigenic sin and apoptosis in the pathogenesis of dengue hemorrhagic fever. *Nature Med* 2003;9:921-7.