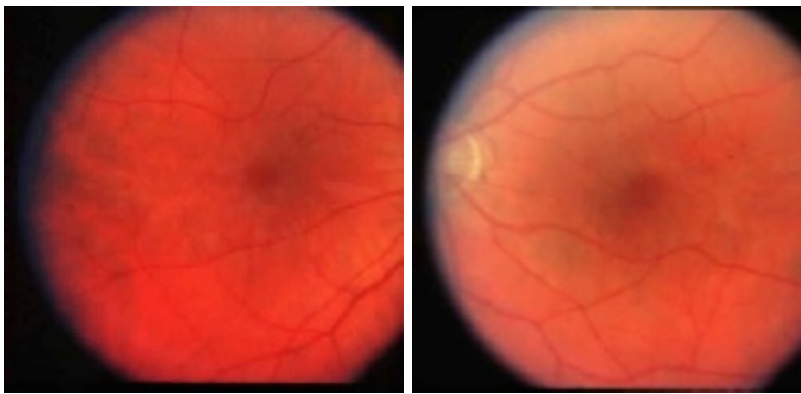


Bilateral Chorioretinal Lesions Appearing Late in Posterior Uveitis

Vakur Pinar MD
Stephen Foster MD

Case Report

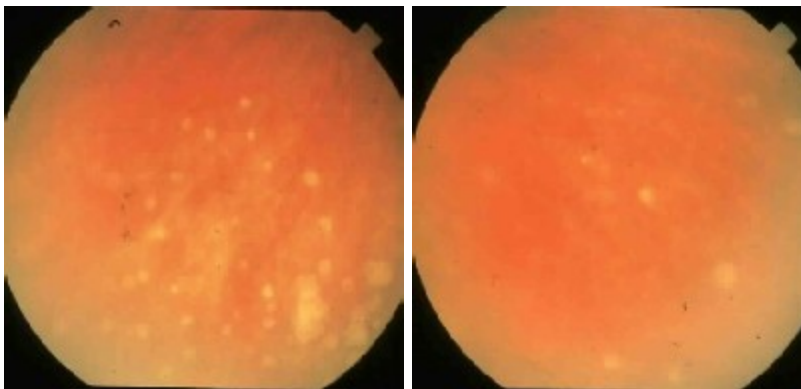
A 64 - year old white woman experiencing blurry vision in both eyes presented in September, 1993. Her past ocular history revealed bilateral uveitis which was diagnosed 4 years previously. She had had 4 flare-ups since then which improved with systemic corticosteroids. She was taking Prednisone, 30 mg/ every other day at her presentation. Her past medical history was significant with muscular aches, sinus problems, chills, night sweats, and fatigue. Her visual acuity was 20/25 OU. Slit-lamp examination showed trace flare and no cells in the anterior chamber of both eyes. Ophthalmoscopic examination showed vitreous opacities and mild epiretinal membranes (ERM) in both maculae as seen in the figures below.



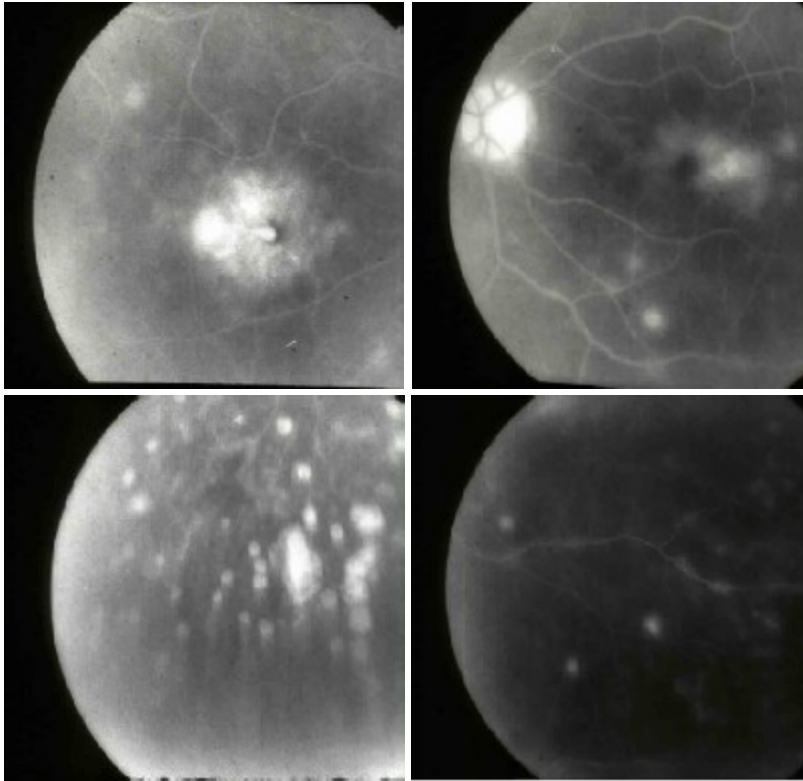
Laboratory work-up, including FTA-ABS, serum lysozyme and angiotensin converting enzyme (ACE) PPD and chest X-ray was normal.

On follow-up 1 year later, the patient came complaining of decreased vision in both eyes, more so in the right eye. VA at that time was 20/40 OD and 20/30 OS. There were flare 1+ and cells 1+ in the anterior chamber of both eyes. There were vitreous cells (3+) in the right eye and ERM's OU. Topical steroid every 2 hours was started and transeptal Kenalog 40 mg was administered to the right eye. One month later, fundus examination revealed decreased vitreous reaction (cells 1+) OU, cystoid macular edema (CME) OD and multiple round, yellow chorioretinal infiltrates in the peripheral retina of the right eye.

Because the work-up, including for syphilis, sarcoidosis and tuberculosis was negative, diagnostic vitrectomy was done in the right eye on 11/21/94. Cytologic examination of the vitreous specimen was negative for malignant cells. Two months later (12/94), similar round, yellow chorioretinal lesions appeared in the posterior and peripheral retina of the left eye and there was CME OU as seen below.



Fluorescein angiography (FA) showed significant CME OU and early hyperfluorescence of the chorioretinal lesions and staining of the small vessels. (See FA below).



Prednisone 40 mg/d was started with slow tapering. The patient had cataract extraction with posterior chamber IOL implantation in her right eye on 7/17/95. Prior to her operation she had no active inflammation in both eyes and after surgery she had been doing well with Pred-Forte qid and Prednisone 10 mg/d.

On her last examination in 10/8/96, her VA was 20/30 OD and 20/50 OS. Slit-lamp examination revealed trace flare and rare cells OU, posterior subcapsular cataract OS and vitreous cells 1+ OU. Fundus examination showed multiple round, atrophic, punched-out chorioretinal lesions OU. She was in stable condition with only Dolobid 500 mg/d; by mouth.

This case is an example of multifocal choroiditis and panuveitis (MCP) who was followed-up closely, with a relatively good response to systemic corticosteroids and with a good prognosis.

MULTIFOCAL CHOROIDITIS AND PANUVEITIS (MCP)

In 1973, Nozik and Dorsch described 2 patients with bilateral anterior uveitis associated with a chorioretinopathy resembling the presumed ocular histoplasmosis syndrome (POHS) (1). In 1984, Dreyer and Gass presented their series of 28 patients with uveitis and similar lesions at the level of the retinal pigment epithelium (RPE) and choriocapillaris, and called the syndrome multifocal choroiditis and panuveitis (2). In 1985, Deutsch and Tessler described 28 patients with a similar condition, which they called inflammatory pseudohistoplasmosis, but most of these patients had findings to suggest systemic diseases such as sarcoidosis, syphilis, or tuberculosis (3). Finally, in 1986, Morgan and Schatz reported 11 similar cases of a condition they called recurrent multifocal choroiditis(4). These four reports all describe a condition with fundus lesions that mimics POHS but with the addition of vitritis and, often , an anterior uveitis. MCP is one of the most common white dot chorioretinal inflammatory syndromes (1,2,4)

Clinical features

Patient characteristics and symptoms

Multifocal choroiditis and panuveitis primarily affects women (75%-100%). The ages have varied from 6 to 69 years, but most patients are in their thirties. There appears to be no racial predilection. Most patients give no history of living in areas endemic for POHS nor do they have affected family members. Most patients have bilateral involvement (45%-79%) but there may be asymmetric involvement and many of the involved second eyes may be completely asymptomatic. Patients usually present subacutely with decreased central vision or metamorphopsia.

Other less common presenting complaints include paracentral scotomata, floaters, photopsias, mild ocular discomfort, and photophobia. Initial visual acuity is highly variable, ranging from 20/20 to light perception.

Anterior uveitis

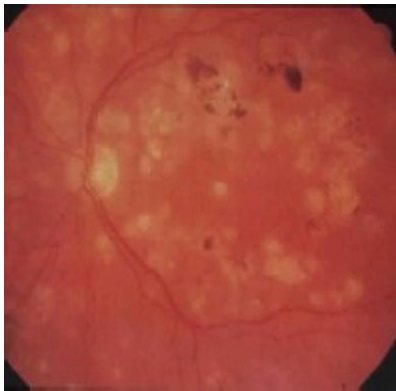Anterior uveitis in MCP (46%-89%) may consist of mild to moderate cellular reaction in the anterior chamber, nongranulomatous keratic precipitates, and posterior synechia. In POHS, the anterior chamber is notably clear.

Vitritis

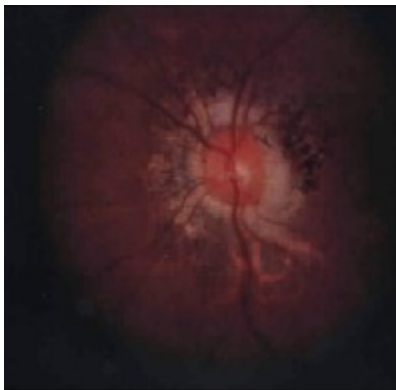
MCP differs from POHS clinically in a number of ways, the most important being the presence of vitritis in one or both eyes. In fact, the presence of vitreous cells in an eye effectively eliminates the diagnosis of POHS. Vitritis was observed in all of the patients in the series of Nozik and Dorsch, and Dreyer and Gass and in 89% of the patients in Deutsch and Tessler's series. The vitritis ranges from mild to moderate and may be asymmetrical. Little vitreous debris is seen once the active inflammation quiets down.

Chorioretinal lesions

The key finding in MCP is the chorioretinal lesions scattered in the fundus. Acutely, several to several hundred yellow (sometimes gray) lesions are seen at the level of the RPE and choriocapillaris. Most lesions are 50 to 350 μ m in diameter but occasionally may be larger. In contrast, the lesions in POHS tend to be larger (300 to 1000 μ m) and fewer (less than 10) (5). The lesions are usually round or oval in shape and may be seen in the posterior, mid-peripheral or peripheral retina. They may be seen singly, in clusters, or arranged in a linear configuration (linear streaks) in the equatorial region (6). These lesions eventually become deep, round and atrophic, with variable degrees of pigmentation and scarring (Figure 9). New chorioretinal lesions may be seen in conjunction with old scars in recurrences.



Typically, most patients develop peripapillary scarring similar to that seen in POHS (white, napkin-ring like). (Figure 10) Optic disc pallor and narrowing of the retinal vessels is much less frequently seen. Cystoid macular edema (CME) occurs in 10% to 20% of patients.



About 25% to 39% of patients with MCP develop macular and peripapillary choroidal neovascular membranes (CNVM's) which may be the presenting cause for decreased vision. Macular CNVM with extensive scarring is the major cause of visual loss in MCP.

In fluorescein angiography acute lesions hyperfluoresce early and leak late. Old scars typically act as window defects with early hyperfluorescence and late fading.

In Dreyer and Gass's series electroretinography has been reported to be normal or borderline (41%), moderately reduced (17%) or severely reduced (21%) (2).

Visual field testing may reveal blind spot enlargement, scotomata corresponding to the chorioretinal lesions, or large temporal field defects which do not necessarily have corresponding fundus lesions.

Clinical course

MCP tends to be a chronic disorder lasting several months to years. Recurrent bouts of inflammation are the rule and may occur in one or both eyes, either separately or simultaneously. New lesions can occur anywhere in the fundus. CNVM's may be present initially or develop late in the follow-up. Because of the chronic and recurrent nature of MCP, patients need to be followed closely. The visual prognosis in MCP is guarded, mostly due to choroidal CNVM's which occur in about one third of the patients.

Etiology

The cause of MCP is not fully understood. Tiedeman suggested a viral etiology when he found serologic evidence of chronic or persistent Epstein-Barr virus (EBV) infection in 10 patients with MCP which he did not find in 8 control patients(7). A subsequent study by Spaide et al. did not support this hypothesis(8). Moreover, patients with MCP do not have systemic signs of chronic EBV infection. In another recent study 7 cases of MCP were evaluated. The presence of specific antibodies in the aqueous and serum suggested recent infection with herpes zoster in 2 cases and herpes simplex in 2 cases (9). It is possible that an exogenous pathogen(s) whether viral, bacterial or fungal, initially triggers an immune response which can lead to subsequent exacerbations in the absence of the inciting pathogen. This is clearly true in POHS. Additional work is needed to more clearly define the cause of MCP.

Differential diagnosis

The most important condition to consider in the differential diagnosis of MCP is POHS, since the fundus appearance in both entities, including peripapillary scarring, chorioretinal lesions (sometimes as linear streaks) and CNVM can be very similar. MCP differs from POHS in the following aspects: (1) Vitreous cells are present, often with anterior uveitis; (2) active, new chorioretinal lesions may develop in the follow-up; (3) most patients come from nonendemic histoplasmosis areas and have negative histoplasmin skin tests; (4) lack of HLA-DR2 specificity, which is often present in POHS (10); (5) a female sex predilection in MCP, and it may occur in children; (6) the ERG may be abnormal in MCP.

Patients with birdshot chorioretinopathy are usually older, have more often bilateral involvement and distinctive, discrete, cream colored or depigmented spots strewn throughout the fundus which are rather distinct from the chorioretinal lesions seen in MCP. In addition, HLA-A29 specificity in BCR helps greatly in the differential diagnosis.

Multiple evanescent white dot syndrome (MEWDS) primarily affects young women but the presentation is more often acutely, it is usually unilateral, the small gray-white lesions are at RPE level and usually confined to the posterior retina, there is typical orangish macular granularity. It is self-limited (average 8 weeks) with a return of visual acuity to 20/20-20/40, and it rarely recurs.

Punctuate inner choroidopathy (PIC), described by Watzke et al., resembles closely MCP (11). Patients with PIC are young, moderately myopic women and usually present acutely with blurred central vision, flashing lights and small central or paracentral scotomas. There is usually no intraocular inflammation, chorioretinal lesions appear all at one time, are confined to the posterior and mid-peripheral retina, and it does not usually recur, unlike MCP. Visual prognosis is good and no treatment is needed except for the 25% of eyes that develop a CNVM.

Other diseases that should be considered in the differential diagnosis of MCP include sarcoidosis, syphilis, Lyme disease, miliary tuberculosis, intraocular lymphoma, herpes virus infection, inflammatory bowel disease and outer retinal toxoplasmosis. These diseases usually have other characteristic clinical and/or laboratory findings that help in differentiation.

Treatment

Periocular or systemic corticosteroids have been used to treat MCP although the best therapy for MCP is still not clear. In Dreyer and Gass's report, 6 of 18 patients had improvement of vision with steroid therapy and 2 additional patients believed that the steroids halted a rapid loss of vision. There was no change in 9 patients (2). Morgan and Schatz reported that all of the patients in their series whom they treated with systemic or periocular steroids responded well and in one patient with a macular CNVM shrinkage of the membrane and improvement in visual acuity was observed (4). Dreyer and Gass treated a similar patient with oral steroids but without any effect on the CNVM (2). Nussenblatt and Palestine observed a moderately good response to steroids but noted that the disease can be stubbornly chronic, and in such cases they recommend consideration of other immunosuppressive drugs, e.g. cyclosporine (12). Clinicians should avoid the mistake of continuing corticosteroids when there appears

to be little effect. Extrafoveal membranes can be treated with laser along with oral corticosteroids. Unlike those of POHS, macular CNVM's in MCP have often extensive fibrosis, making the surgical removal of submacular neovascular nets most difficult (13).

REFERENCES

1. Nozik RA, Dorsch W : A new chorioretinopathy associated with anterior uveitis, *Am J Ophthalmol* 76: 758-762, 1973.
2. Dreyer RF, Gass JDM : Multifocal choroiditis and panuveitis : a syndrome that mimics ocular histoplasmosis, *Arch Ophthalmol* 102: 1776-1784, 1984.
3. Deutsch TA, Tessler HH : Inflammatory pseudohistoplasmosis, *Ann Ophthalmol* 17: 461-465, 1985.
4. Morgan CM, Schatz H : Recurrent multifocal choroiditis, *Ophthalmology* 93: 1138-1147, 1986.
5. Joondeph BC, Tessler HH : Multifocal choroiditis, *Int Ophthalmol Clinics* 30(4) : 286-290, 1990.
6. Spaide RF, Yannuzzi LA, Freund BK : Linear streaks in multifocal choroiditis and panuveitis, *Retina* 11(2): 229-231, 1991.
7. Tiedeman JS : Ebstein-Barr viral antibodies in multifocal choroiditis and panuveitis, *Am J Ophthalmol* 103: 659-663, 1987
8. Spaide RF, Sugin S, Yannuzzi LA, DeRosa JT : Ebstein-Barr virus antibodies in multifocal choroiditis and panuveitis, *Am J Ophthalmol* 112: 410-413, 1991.
9. Frau E, et al. : The possible role of herpes simplex virus in multifocal choroiditis and panuveitis, *Int Ophthalmol* 14: 365-369, 1990.
10. Spaide RF, Skerry JE, Yannuzzi LA, DeRosa JT : Lack of the HLA-DR2 specificity in multifocal choroiditis and panuveitis, *Br J Ophthalmol* 74: 536 537, 1990.
11. Watzke RC, Packer AJ, Folk JC et al. : Punctate inner choroidopathy, *Am J Ophthalmol* 98: 572-584, 1984.
12. Nussenblatt RB, Whitcup SM, Palestine AG : Uveitis: fundamentals and clinical practice. Mosby-Year Book, Inc.2nd ed. : 373-375, 1996.
13. Nolle B, Eckardt C : Vitrectomy in multifocal choroiditis, *Ger J Ophthalmol* 2: 14-19, 1993.
14. Gass DJ. *Stereoscopic Atlas of Macular Diseases*, 4th ed. Vol.2 Mosby-Year Book, Inc.,1997; 688-693.
15. Reddy CV, Folk JC. Multifocal choroiditis with panuveitis, diffuse subretinal fibrosis, and punctate inner choroidopathy. In: Ryan SJ, Schachat AP, Murphy RP eds. *Retina* 2nd ed. Mosby-Year Book, Inc.,1994; Vol 2, chap.105.